

CASE REPORT

MJPC Vol. 29 (3) December 2023

OFFICIAL JOURNAL



PRIMARY PAROTID TUBERCULOSIS IN A TODDLER

Iffah Salim^{1,2}, Nazil Azadi Mohd Azlan², Carren Teh², Irfan Mohamad^{1*}

Abstract

Tuberculosis (TB) of the parotid gland is a rare disease and occurs less frequently in children. Re-emergence is seen amongst immunocompromised individuals whose diagnosis may be overlooked, leading to unnecessary surgery. Diagnosis is challenging in the absence of systemic constitutional symptoms and depends mainly on the treating physician having a strong suspicion. We report a rare extrapulmonary manifestation of TB involving the parotid gland in an otherwise immunocompetent child. A 2-year-old girl presented with a mass in the right parotid region that had been present for 3 months. A similar swelling was treated with an antibiotic 3 months prior, but it recurred. The mass was painful, firm, erythematous, and located in the infra-auricular region. Symptoms persisted after 2 courses of antibiotics, after which ultrasonography was performed and the intra-parotid collection was aspirated, which was positive for acid-fast bacilli (AFB). The patient was placed on anti-TB treatments. Although uncommon, TB should be considered in patients with a solitary mass in the parotid gland to avoid unnecessary surgery.

Keywords: Parotid; Tuberculosis, Extrapulmonary, Paediatric

DOI: 10.51407/mjpc.v29i3.260

Received: 17 May 2023; **Accepted revised manuscript:** 15 August 2023; **Published online:** 9 November 2023

Introduction

Mycobacterium tuberculosis (MTB) infection can cause pulmonary and extrapulmonary diseases. Lymph node tuberculosis (TB) is the most common form of extrapulmonary TB. However, isolated parotid gland involvement is rare in countries where TB is prevalent. Diagnosis can be challenging in the absence of pulmonary TB symptoms and a history of exposure, especially in children. Parotid TB may present similarly to other parotid gland neoplasms. The treating physician may overlook this entity, and the patient may undergo unnecessary surgery.

Case Presentation

A 2-year-old girl presented with a swelling of the right neck that had been present for 3 months. The swelling was associated with mild pain, but there was no history of fever, trauma, ear discharge, scalp injury, or cat scratch. Approximately 3 months earlier, she had a similar swelling that was treated with two courses of antibiotics by a general practitioner. After completion of the two separate courses of antibiotics therapy, the swelling decreased significantly and almost disappeared. However, the swelling then recurred in the exact location. Otherwise, she has no persistent cough, haemoptysis, loss of appetite or

weight, or night sweats. There was no history of TB in the family or recent travel to endemic areas.

Examination revealed a firm, tender, and erythematous 3.0 x 1.5 cm right infra-auricular swelling. However, there was no punctum, and the swelling was not fluctuant. There were no other palpable nodes in the neck, axillary or inguinal region. The white blood cell count was not elevated, the Mantoux test was 10 mm, and the chest radiograph was unremarkable. She received another two courses of oral antibiotics, co-amoxiclav, and cefuroxime, one week each, but subsequent follow-ups showed persistent swelling.

Ultrasonography (USG) revealed 2 irregular hypoechoic collections in the right parotid gland measuring 1.2 x 0.9 cm and 1.1 x 0.9 cm, respectively,

¹Department of Otorhinolaryngology-Head and Neck Surgery, School of Medical Sciences, Health Campus, Universiti Sains Malaysia, 16150 Kubang Kerian, Kelantan, Malaysia.

²Department of Otorhinolaryngology-Head and Neck Surgery, Jalan Hospital Sungai Buloh, 47000, Sungai Buloh, Selangor, Malaysia

*Corresponding Author:

Irfan Mohamad, Department of Otorhinolaryngology-Head and Neck Surgery, School of Medical Sciences, Health Campus, Universiti Sains Malaysia, 16150 Kubang Kerian, Kelantan, Malaysia

Telephone: +609-7676420 **Email:** irfankb@usm.my

and the parotid parenchyma of the right parotid gland appeared more echoic compared with the left parotid gland, suggesting acute right parotitis with intraparotid abscesses. There were also multiple enlarged cervical lymph nodes along the right posterior cervical space and submandibular region. Aspiration of the intraparotid collection was performed, and the pus was examined for culture and sensitivity (C&S), acid-fast bacilli (AFB), and MTB C&S. The pus for C&S was no growth, AFB was positive (3-24 AFB in one length), and MTB C&S was negative. Thus, the diagnosis TB of the right parotid gland was made, and she was referred to paediatrics team on the decision to initiate anti-TB.

She received six months of treatment for TB under the local directly supervised treatment program (DOTS), in which she received four drugs (rifampicin, isoniazid, pyrazinamide, ethambutol) in the intensive phase for the first two months, followed by two drugs (rifampicin and isoniazid) in the maintenance phase for four months. She was tested for HIV to determine an immunocompromised state, which was negative, and other family members were screened for TB, which was also negative. The swelling decreased significantly after 2 months of intensive anti-TB and resolved completely after a total of 3 months of anti-TB. She completed her maintenance therapy for a total of 4 months. At the end of treatment, an USG of the neck was performed, which showed resolution of the right intraparotid collection and cervical lymphadenitis.

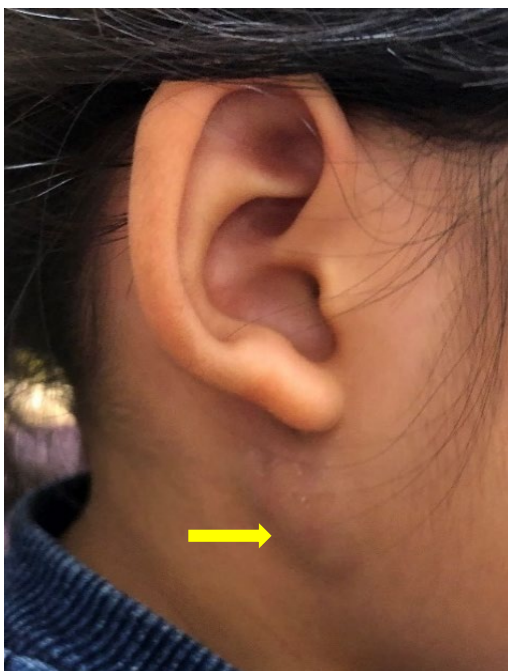


Figure 1. Right parotid swelling with overlying erythematous skin (arrow).

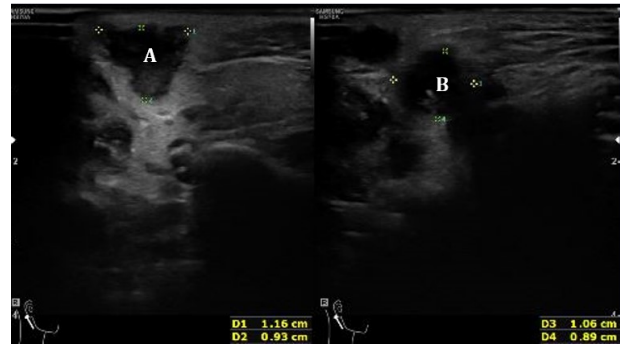


Figure 2. USG revealed two irregular hypoechoic collections in the right parotid gland measuring 1.2 x 0.9 cm (A) and 1.1 x 0.9 cm (B).

Discussion

Tuberculosis (TB) infections are endemic in developing countries and are increasing in industrialised countries in association with resistant strains and Human immunodeficiency virus (HIV) co-infections [1]. The World Health Organisation (WHO) estimates that 10.6 million people worldwide were infected with TB in 2021. Southeast Asia accounted for 45% of global TB cases, followed by Africa (23%), the Western Pacific (18%), with smaller proportions in the Eastern Mediterranean (8.1%), North and South America (2.9%), and Europe (2.2%) [2].

TB can affect any organ system. Pulmonary TB remains the most common form of TB and accounts for three-quarters of TB infections, while the rest is caused by extrapulmonary TB (EPTB) [3]. The most common form of EPTB in the head and neck region is lymph nodes with 35.6%, larynx (27.4%), oropharynx (13.7%), salivary gland (12.3%), sinuses and ear (4.1%), and the least common is skin in the head and neck region [4].

TB of a salivary gland is rare but commonly infects the parotid gland and may affect all age groups [4,5]. The most common route of infection to the parotid glands is ascending infection from the oral cavity into the ductal system and then into the salivary gland. The rare possible route is hematogenous spread from a primary source in the body or via lymphatic spread from the tonsil tissue and auditory canal into the intraparotid and periparotid lymph nodes [1,3,6].

Clinically, the presentation of parotid gland TB is non-specific and may mimic neoplasm. Clinicians should always have a high index of suspicion, especially in endemic areas. Rarely, systemic symptoms such as fever, malaise, loss of appetite, or weight loss occur [5]. The parotid gland TB usually presents as a localised parotid mass, with the nature of the mass ranging from firm-to-hard (due to infection of the intracapsular or pericapsular lymph nodes) to a

fluctuating mass if an abscess has formed. In addition, it may present as a periauricular fistula or diffuse glandular swelling if the gland parenchyma is involved [1,4,6].

There are no specific radiological signs of tuberculosis infection [7]. However, high-resolution USG is readily available, radiation-free, and can distinguish possible benign from malignant neoplasms and show whether the mass originates in the parotid parenchyma or periparotid area [3,5]. Fine needle aspiration (FNA) of parotid lesion remains the gold standard for diagnosing parotid mass with a sensitivity of 81-100% and a specificity of 94-100% [5]. USG-guided FNA is helpful in detecting intraparotid lymph nodes.

The diagnosis of TB infection still relies on the identification or isolation of *M. tuberculosis* bacilli from a clinical specimen. The detection can be done by classical smear microscopy for AFB, which is rapid and readily available. However, the positivity of the result depends on the bacilli load of the specimen and the type of specimen, which in EPTB is usually paucibacillary, so polymerase chain reaction (PCR) techniques or mycobacterial culture may be required. Culture is a more sensitive method that provides information about drug sensitivity, especially for second-line drugs in cases of multidrug resistant TB. However, due to the slow growth of the organism, it may take up to 6 weeks for a culture to be positive [6–8].

According to the Infectious Disease Society of America (IDSA), a positive AFB smear from a suspected EPTB site can be used as evidence of extrapulmonary TB and guide decision-making because false-positive results are unlikely, and a negative mycobacterium culture should not be used to exclude TB because false-negative results are extremely common. In this patient, 6 weeks of incubation of mycobacterium culture showed no growth. Despite that, treatment is still necessary as the clinical suspicion is high. On the contrary, evidence suggests that this cohort of patients (children <5 years of age), they are at high risk of developing active TB from latent TB infection (LTBI) [9].

Because of the efficacy of medical therapy, treatment with conventional anti-TB drugs for at least 4-6 months remains the mainstay of parotid TB treatment [3,5,6]. The WHO recommended that children diagnosed with TB should undergo HIV screening, as their risk is eight times higher than non-HIV positive children. In addition, other immune-suppressive conditions, whether primary or secondary immunodeficiency, such as malnutrition, vitamin D

deficiency, and diabetes, should be investigated as they could disrupt the host defence mechanism leading to TB infection [10]. Surgical intervention is reserved for drug-resistant TB and after trial of medical treatment to allow sterilization of tuberculous area and disappearance of parotid tumour syndrome [3,5].

Hence, we recommend sending specimens for TB in non-resolving infections of parotid gland especially in endemic countries as EPTB can mimic other diseases and may affect all age groups.

References

- [1] Birkent H, Karahatay S, Akcam T, Durmaz A, Ongoru O. Primary parotid tuberculosis mimicking parotid neoplasm: A case report. *Journal of Medical Case Report*. 2008;2(1):62.
- [2] European Centre for Disease Prevention and Control (ECDC). Tuberculosis surveillance and monitoring in Europe 2023 - 2021 data. 2023 [cited 2023 Mar 27].
- [3] Garg R, Verma SK, Mehra S, Srivastawa A. Parotid tuberculosis. *Lung India* 2010;27(4):253–5.
- [4] Mohamad AN, Mohamad I, Haron A, Salahuddin Z. Unusual presentations of tuberculosis – A case series. *Egyptian Journal of Ear, Nose, Throat and Allied Sciences*. 2016;17(3):155–8.
- [5] Borki R, Bouti K, Lahma J, Bouadel N, Rkain I, Nitassi S, et al. Tuberculosis of the parotid gland in children - A report of 4 cases. *International Journal of Medicine and Surgery*. 2015;2(2):40–3.
- [6] Babazade F, Mortazavi H, Jalalian H. Parotid tuberculosis: A forgotten suspicion (a case report and literature review). *International Journal of Dermatology*. 2012;51(5):588–91.
- [7] Elango S, Prema S, Vijayakumar AR, Sravani N, Nagarajan K, Vijayalakshmi G. Unusual manifestations of extra-pulmonary tuberculosis: A pictorial essay. *Polish Journal of Radiology*. 2022;87(1):79–86.
- [8] Heemskerk D, Caws M, Marais B, Farrar J. Tuberculosis in adults and children. 1st ed. Cham: Springer International Publishing. 2015.
- [9] Lewinsohn DM, Leonard MK, Lobue PA, Cohn DL, Daley CL, Desmond E, et al. Official American thoracic society/Infectious diseases society of America/Centers for disease control and prevention clinical practice guidelines: diagnosis of tuberculosis in adults and children. *Clinical Infectious Diseases*. 2017 Jan 15;64(2):111–5.
- [10] Whittaker E, Lopez-Varela E, Broderick C, Seddon JA. Examining the complex relationship between tuberculosis and other infectious diseases in children: A review. *Frontiers in Paediatric*. 2019;7(233):2296-360.