

CASE REPORT

MJPC Vol. 27 (1) June 2021

OFFICIAL JOURNAL



DOCTOR, MY CHEST IS DEFORMED....

Nur Shafinaz Rusli¹, Syed Abdul Khaliq bin Syed Abdul Hamid¹, Norhafiza bt Ab. Rahman², Azian bt Abd. Aziz³, Ahmad Fadzil bin Abdullah¹

ABSTRACT

Congenital chest wall deformities occurred in roughly 1% of children and if asymptomatic are often overlooked and taken lightly. This results in a progressive deformity of the chest and delays in diagnosis of the underlying causes. Complications can also develop from the underlying condition. Chest wall deformities are associated with a number of syndromes and other anomalies including abnormalities of the diaphragm. Congenital Diaphragmatic Hernia (CDH) is one of the underlying causes of chest deformity. Congenital Morgagni Hernia (CMH) is a rare form of CDH and consists of 3-5% in all CDH. Many cases were delayed in diagnosis due to the subtle presentation or were incidental findings. The consequence of delay in diagnosis can lead to the onset of complications which carries morbidities and even mortality. We report a case of a child with missed diagnosis of a rare condition Morgagni Diaphragmatic Hernia presenting with chest deformity.

Keywords: Chest Asymmetry, Asymptomatic Chest Deformity, Morgagni Congenital Diaphragmatic Hernia

DOI: 10.51407/mjpc.v27i1.131

Received: 19 November 2020; **Accepted revised manuscript:** 19 May 2021
Published online: 20 June 2021

Introduction

Congenital chest wall deformities are anomalies in chest wall growth. Chest deformities were reported in 1.41% in children between 11-14 years of age and are more common in male. [1] These can be categorized to either rib cage overgrowth or deformities related to inadequate growth (aplasia or dysplasia). The commonest of these is pectus excavatum, also known as an "excavated, sunken, or funnel chest," which constitutes 88% of chest deformities [2]. Pectus excavatum could present as isolated non-familial deformity or familial non-syndromic deformity. Pectus excavatum can also be part of genetic syndromes such as Noonan, Marfan, Ehler Danlos and Hurler syndrome [2-3]. Pectus excavatum has also been reported in patients with diaphragmatic agenesis and congenital diaphragmatic hernia [4-5]. Other conditions that can present with pectus excavatum include cardiac problems such as mitral valve prolapse,

arrhythmias and congenital heart disease [3]. Pectus carinatum comprises around 5% of chest wall deformities [3]. The less common types of chest wall deformities are described in patients with Poland syndrome, Ectopia Cordis, Jarcho-Levine Syndrome and Jeune syndrome or asphyxiating chondrodystrophy. Chest deformities are also found in patients who have intrathoracic abnormalities such as Congenital Diaphragmatic Hernia (CDH), lung agenesis and lung hypoplasia [4-5]. Chest deformities could be present since birth or it could be progressive. It could become more pronounced during rapid

¹Department of Pediatrics, Sultan Ahmad Shah Medical Centre @ IIUM, 25200 Kuantan, Pahang Darul Makmur, Malaysia

²Department of Surgery, Sultan Ahmad Shah Medical Centre @ IIUM, 25200 Kuantan, Pahang Darul Makmur, Malaysia

³Department of Radiology, Sultan Ahmad Shah Medical Centre @ IIUM, 25200 Kuantan, Pahang Darul Makmur, Malaysia

Corresponding Author:

Nur Shafinaz Rusli, Department of Pediatrics, Sultan Ahmad Shah Medical Centre @ IIUM, 25200 Kuantan, Pahang Darul Makmur, Malaysia

Tel.: +6095912543 **Email:** nurshafinazrusli@iium.edu.my

pubertal growth [6]. Unfortunately, many parents were not properly advised and were informed that these deformities will correct themselves when the children grow. This is a missed opportunity to look for the underlying causes that can be treated and thus correcting the chest deformities.

Congenital Morgagni Hernia (CMH) is rare and it consists of 3-5% in all types of CDH [7]. In 18 years' period, there were a total of 20 cases of CMH treated in a major hospital in Saudi Arabia. Majority of them present with recurrent chest infection and were diagnosed after neonatal period before the age of one year old [7]. Whereas, 3 out of these 20 cases aged 6 months, 9 months and 5 years old respectively were incidental findings. We report a case of a 2-year-old boy with Morgagni Diaphragmatic Hernia who has chest deformity since birth but was dismissed as self-limiting and only diagnosed incidentally when he presented to the Emergency Department due to a fall.

Case Report

A 2-year-old boy had a fall and was brought to Emergency Department in a private hospital. He had extensive bruises over his face and his full blood count shown low platelet count. He apparently had upper respiratory tract infection (URTI) a week ago. He was admitted to a private hospital and treated for Idiopathic Thrombocytopenic Purpura (ITP). He was also noted to be having asymmetrical chest deformity where there was a depression at the right lower anterior chest wall. (Figure 1)

The mother gave the history of deformed chest since birth and was seen by many doctors especially when he had URTI. Since the child was asymptomatic, they were told not to worry about it and were informed that the deformed chest will correct itself. The deformed chest however became more prominent as he grew up. He has a good effort tolerance and able to play like any normal children. There was no clubbing of his fingers and he was not dysmorphic. On examination, there was a depression over the lower anterior chest wall, reduced chest expansion over the right lower chest with reduced note on percussion over the chest depression. His chest auscultation revealed a slightly reduced air entry on the right side

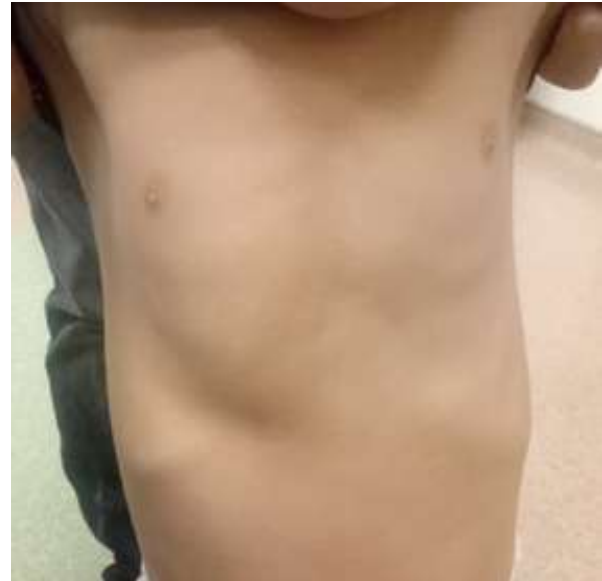

Figure 1. Chest depression at right lower anterior chest wall.

without any added sound. The initial chest x-ray (Figure 2) showed right lower zone consolidation but no bony abnormality was detected. He was presumed to have bronchopneumonia and treated with antibiotic.

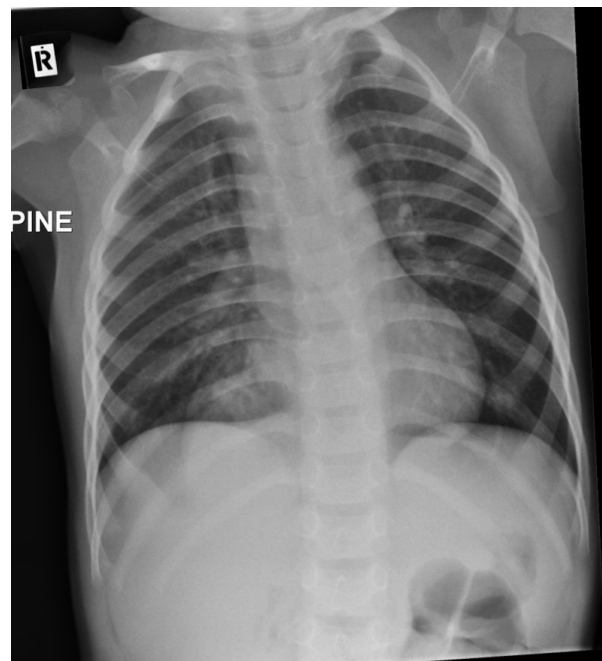


Figure 2. CXR shows a right paracardiac consolidation with hyperinflated lung fields bilaterally.

He was seen 3 weeks later by a pediatrician for follow up. The subsequent chest x-ray showed persistent right lower lobe consolidation. Hence, CT scan thorax was done and revealed a right-sided CDH (Morgagni hernia) (Figure 3). He was asymptomatic other than the chest deformity (Figure 1). He was then referred to pediatric surgical team and was advised for surgery.

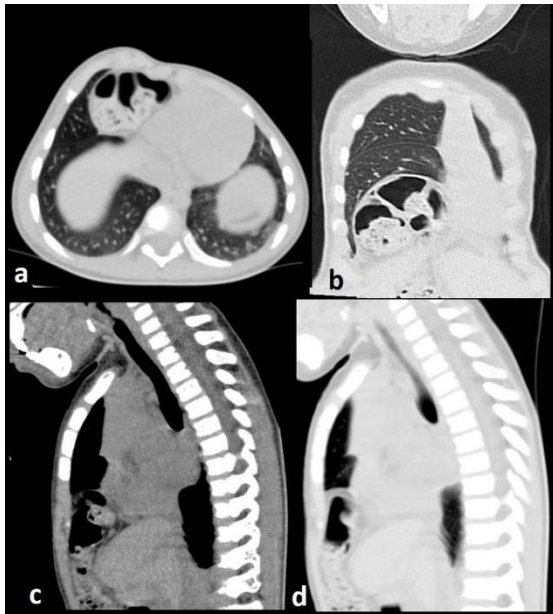


Figure 3. CT thorax: a) axial lung window, b) coronal lung window, c) sagittal soft tissue window, d) sagittal lung window, which demonstrates herniation of bowel loop through a defect at the anterior medial aspect of the right hemidiaphragm into the lower right lung, consistent with a congenital diaphragmatic hernia (Morgagni type).

Discussion

CDH has an incidence between 1 in 3000 to 1 in 5000 per live births [8]. The anteromedial diaphragmatic defect which is a much rarer form is due to defect through the foramen of Morgagni and accounts for 1-6% of diaphragmatic hernia [8]. The defect is caused by the failure of the sternal and crural portion of the diaphragm to fuse. These defects are usually small, with greater at transverse than anteroposterior diameter, and 90% are right-sided [8]. The hernial sac usually contains small bowel, transverse colon and or liver. [9]

The chest deformities in CDH tend to be asymmetric and progressive. The close relationship between development of the lung, diaphragm, and thoracic cavity is the reason for the chest deformities in CDH [10]. The hernia can reduce the size of the thoracic cavity and results in a smaller lung volume. This will increase the work of breathing and higher negative intrapleural pressure is required to inflate the lungs [11]. The increase in intrathoracic pressure promotes retraction of the chest wall in its most compliant section, i.e., the cartilaginous anterior wall [12]. This contributes to the development of the pectus abnormalities of the chest wall.

Majorities of children with Morgagni CDH are asymptomatic after birth and are diagnosed beyond the neonatal period. When symptomatic, patients presented with recurrent respiratory infections, cough, vomiting, reflux or in rare instances, incarceration of the bowel [7,13]. However, many are asymptomatic and the diagnosis can be incidental as in our case where the diagnosis is made after the chest radiograph was done for different reason [7,13]. Complications from delayed diagnosis could arise such as bowel obstruction or strangulation and intermittent volvulus. [14-15]. Mohamed et al reported an adult with CMH who presented with chest pain due to suspected loop of bowel compressing the right side of the chest [17]. There is also death reported in adult due to cardiac compression and cardiac tamponade secondary to CMH [18].

Morgagni CDH is relatively benign, but can become a life-threatening condition with significant because of possible significant morbidities especially the risk of bowel strangulation. Hence, surgical repair is recommended for all patients. This can be done laparoscopically or by an open approach. Patients typically have uncomplicated recovery and very few sequelae.

Conclusion

It is very important for health practitioners who reviewed a child with chest deformity to be cautious and have high index of suspicion especially with asymmetrical deformity although the child is asymptomatic. They must at least do a chest x-ray for initial evaluation. This basic

investigation can help to reduce morbidities if there is an underlying cause related to the chest deformity.

References

- [1] Yucel A., Neslihan GP., Bulent K., Gultekin G., Fatma N. The prevalence of chest wall deformity in Turkish children. *Turk J med Sci* 2018;48:1200-1206.
- [2] Kelly RE, Lawson ML, Paidas CN. Pectus excavatum in a 112-year autopsy series: anatomic findings and the effect on survival. *J Pediatr Surg* 2005;40(8): 1275–8.
- [3] Kotzot D, Schwabegger AH. Etiology of chest wall deformities—a genetic review for the treating physician. *J Pediatr Surg* 2009;44(10):2004–11.
- [4] Tocchioni F, Ghionzoli M, Pepe G, Messineo A. Pectus excavatum and MASS phenotype: an unknown association. *J Laparoendosc Adv Surg Tech A*. 2012 Jun; 22(5):508-13.
- [5] Koumbourlis AC. Chest wall abnormalities and their clinical significance in childhood. *Paediatr Respir Rev*. 2014 Sep;15(3):246-54.
- [6] Ohno K, Nakahira M, Takeuchi S. Indications for surgical treatment of funnel chest by chest radiograph. *Pediatr Surg Int* 2001;17(8):591–5.
- [7] Ahmed H. Al-Salem. Congenital Hernia of Morgagni in infants and children. *Journal of Pediatric Surgery* 2007;42:1539-1543.
- [8] Colvin J, Bower C, Dickinson JE. Outcomes of congenital diaphragmatic hernia: a population-based study in Western Australia. *Pediatrics*. 2005;116:E356–63.
- [9] Hussong RL, Landreneau RJ, Cole FH. Diagnosis and repair of a Morgagni hernia with video-assisted thoracic surgery. *Ann Thorac Surg*. 1997;63:1474–1475.
- [10] Lund DP, Mitchell J, Kharasch V. Congenital diaphragmatic hernia: the hidden morbidity. *J Pediatr Surg*. 1994;29:258–62.
- [11] Vanamo K, Peltonen J, Rintala R. Chest wall and spinal deformities in adults with congenital diaphragmatic defects. *J Pediatr Surg*. 1996;31:851–4.
- [12] Trachsel D, Selvadurai H, Bohn D. Long-term pulmonary morbidity in survivors of congenital diaphragmatic hernia. *Pediatr Pulmonol*. 2005;39:433–9.
- [13] Minneci PC, Deans KJ, Kim P, Mathisen DJ. Foramen of Morgagni hernia: Changes in diagnosis and treatment. *Ann. Thorac. Surg*. 2004;77:1956–9.
- [14] Bhasin DK, Nagi B, Gupta NM, Singh K (1989) Chronic intermittent gastric volvulus within the foramen of Morgagni. *Am J Gastroenterol* 84: 1106–1108
- [15] Eren, S., Gümüş, H. & Okur, A. A rare cause of intestinal obstruction in the adult: Morgagni's hernia. *Hernia* 2003;7: 97–99. <https://doi.org/10.1007/s10029-002-0099-4>
- [16] Arora S, Haji A, Ng P. Adult Morgagni hernia: the need for clinical awareness, early diagnosis and prompt surgical intervention. *Ann R Coll Surg Engl*. 2008;90:694–5.
- [17] Mohamed, M., Al-Hillan, A., Shah, J.. Symptomatic congenital Morgagni hernia presenting as a chest pain: a case report. *J Med Case Reports* 2020;14:13. <https://doi.org/10.1186/s13256-019-2336-9>
- [18] El Bakouri, K. Sylvestre, I. Hamrerras, M. Bouali, K. El Hattabi, F.Z. Bensardi, A. Fadil. Morgagni's Hernia Presented with Respiratory Distress and Lead to Death: A case report and Literature Review. *Asian Journal of Research in Surgery* 2020; 3(1): 1-6.